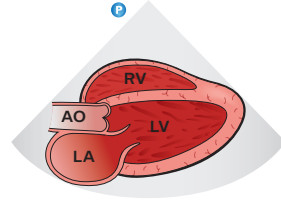
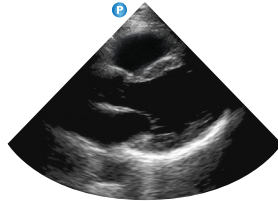
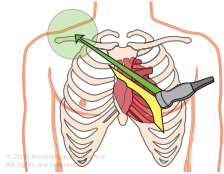
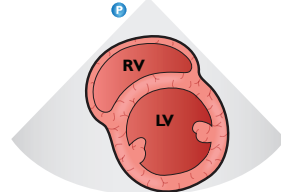
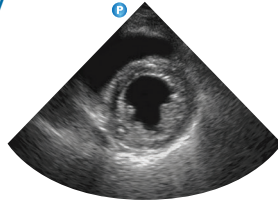
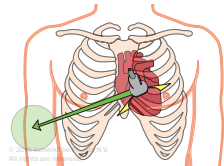


Introduction to TTE – POC views (general orientation)

Parasternal long-axis

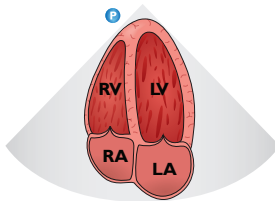
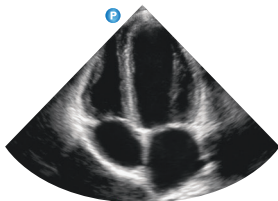
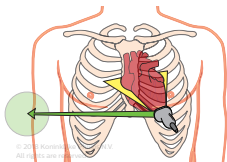


Parasternal short-axis LV



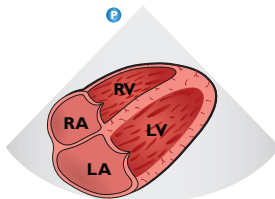
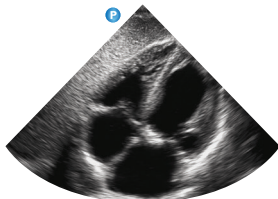
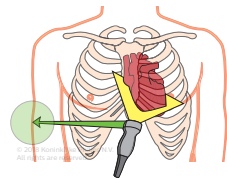
Introduction to TTE – POC views (general orientation)

Apical four-chamber

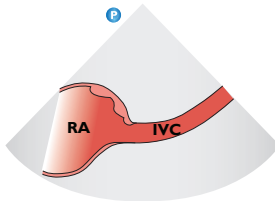
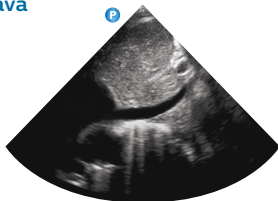
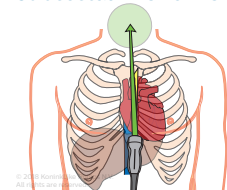


To view the complete
“Introduction to
transthoracic echo”
tutorial visit:
[www.philips.com/
CCEMeducation](http://www.philips.com/CCEMeducation)

Subcostal four-chamber



Subcostal inferior vena cava



©2018 Koninklijke Philips N.V.
All rights are reserved.
Philips reserves the right to make
changes in specifications and/or
to discontinue any product at any
time without notice or obligation
and will not be liable for any
consequences resulting from the
use of this publication.

ULT-18-38110 * MAY 2018