



**PHILIPS**

Ultrasound

# Elastography in the technically difficult patient

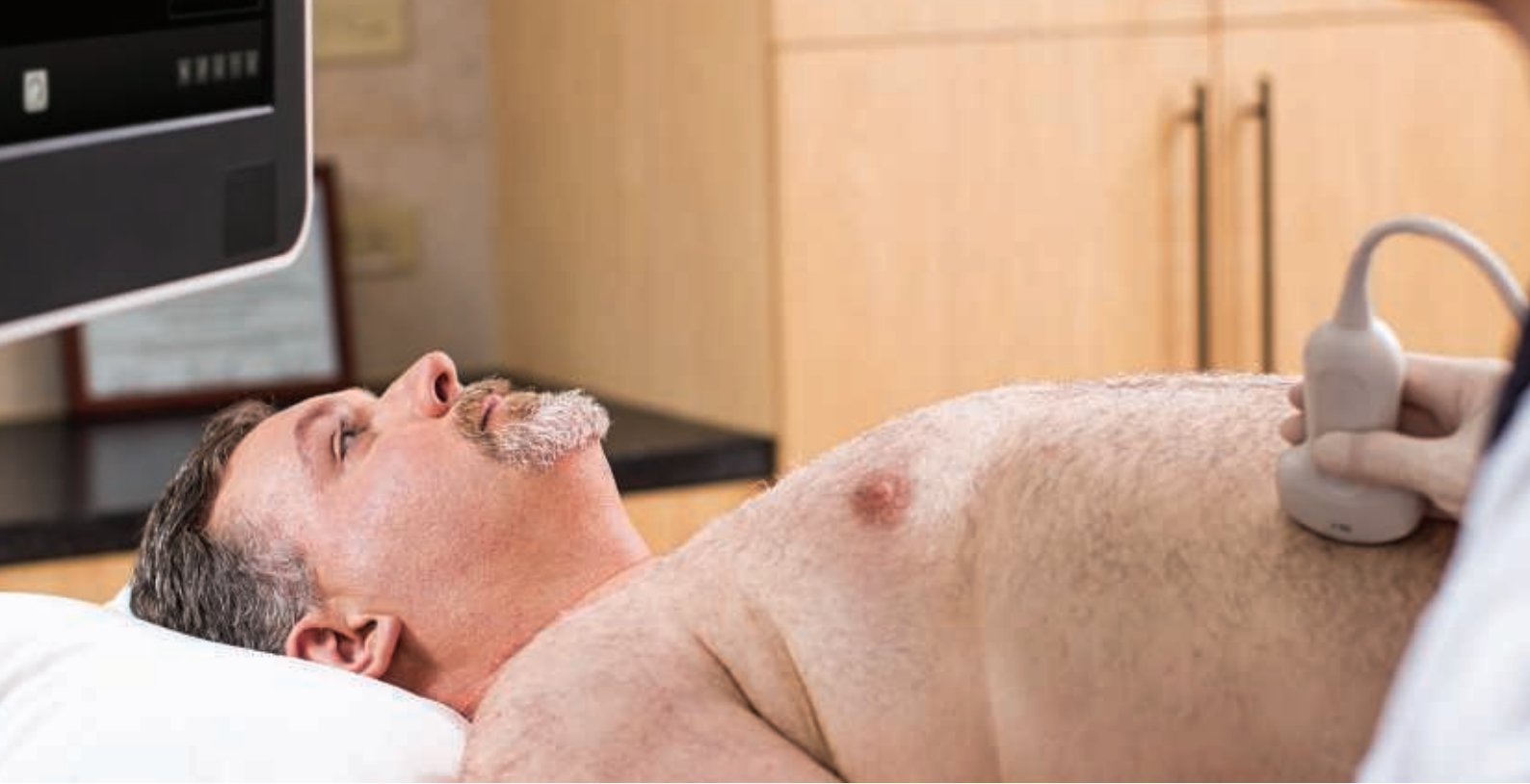EPIQ ultrasound system



**Anthony Lupetin, MD**  
Chairman  
Department of Diagnostic Radiology  
Allegheny General Hospital  
Pittsburgh, PA, USA

“You can offer more information because you’re looking at liver texture along with stiffness, and you can describe the findings during the same exam because you’re performing ultrasound and elastography together.”

**Anthony Lupetin, MD**



# Elastography as a noninvasive tool to **simplify** liver assessment

Philips elastography generates shear waves inside the liver by using acoustic force from a focused ultrasound beam. The system monitors shear wave propagation and measures its velocity, then displays it in an easy-to-interpret format.

Liver shear wave elastography provides stiffness measurements for assessment of diffuse liver disease and possibly neoplastic lesions of the liver. Because it is noninvasive, shear wave elastography can offer a well-tolerated and cost-effective method for diagnostics, follow-up, and monitoring of disease that is an alternative to painful, expensive biopsies for some patients.

Dr. Anthony Lupetin, Chairman of the Department of Diagnostic Radiology at Allegheny Health Network, sees the combination of Philips ultrasound and elastography as valuable in the assessment of liver disease, which is possible even in the technically difficult patient. His team performs two to three elastography exams per day and has performed a total of between 300 and 400 exams last year.

Dr. Lupetin uses the EPIQ 7G system with the C5-1 PureWave transducer to conduct elastography exams.

## **Increasing prevalence of liver disease**

Dr. Lupetin believes that the increasing prevalence of liver disease makes elastography an essential tool for assessment of a range of liver diseases, including nonalcoholic fatty liver disease (NAFLD).

“There are an expected 20 million patients with NAFLD coming down the road,” he says. “There aren’t enough doctors in the world to do all the liver biopsies required to diagnose. Elastography can be used to screen these people, to get them in the right spot for follow-up.”

# Elastography in the technically difficult patient

Remarkable advances of the EPIQ ultrasound system with the C5-1 PureWave transducer have greatly expanded the range of technically difficult patients that Dr. Lupetin is able to scan.

## Case 1: Obesity with chronic HCV

“The difficult aspect was the patient’s size. Regular ultrasound indicated increased fat in the liver. Elastography showed the patient to be cirrhotic. Using ultrasound, we were able to identify that the patient had very advanced liver disease. Because the patient’s size could not have been easily accommodated by a CT or MR scanner due to system weight restrictions and scanner configuration, ultrasound with elastography was a good first option.”

**Anthony Lupetin, MD**

Seeing increased spleen size also helped with the patient assessment.

### Exams

Limited abdominal ultrasound with elastography.

### Findings

**Liver:** Increase in sound attenuation within liver parenchyma consistent with hepatic steatosis. This limits evaluation of the liver parenchyma as much of the posterior liver parenchyma cannot be penetrated. If there is clinical concern for underlying lesion, correlation with MR or CT is recommended. No gross abnormality detected.

**Biliary tree:** No intra- or extra-hepatic biliary dilatation; CBD measures 3 mm

**Gallbladder:** Multiple shadowing stones without wall thickening

**Pancreas:** Obscured by overlying bowel gas and patient’s body habitus

**Spleen:** Measures 18.3 cm

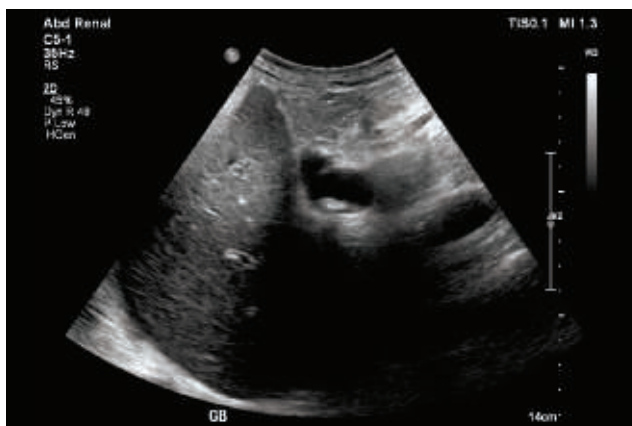**Ascites:** None

### Elastography

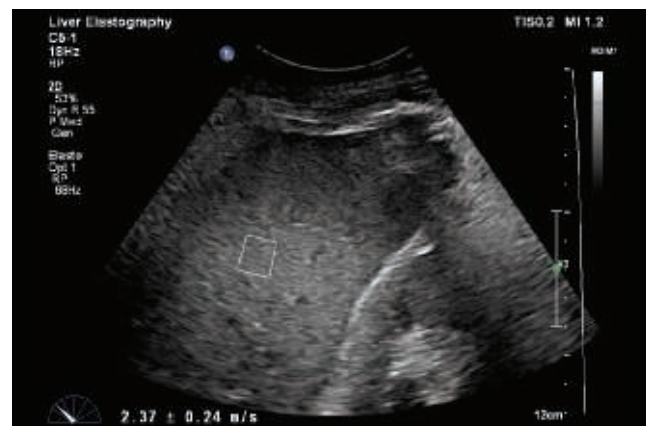
Shear wave velocity measures 2.3 m/sec (mean value of 10 measurements).

### Impression

Metavir score F3/F4 consistent with moderate to severe fibrosis. Heterogeneous hepatic steatosis with borderline splenomegaly. Elastography corresponding to F3/F4 consistent with moderate to severe fibrosis.



Gallbladder packed with stones, posterior shadowing



Liver stiffness measurement with ElastPQ



## Case 2

# Trauma paraplegic with chronic HCV, rule out cirrhosis

Dr. Lupetin used the C5-1 PureWave transducer to assess this patient in a wheelchair without compromising the quality of the examination.

“This was a technically difficult scan because the patient is paraplegic. We were able to perform ultrasound with elastography, which showed us that, despite being infected with HCV, the patient has not progressed to more serious disease and will continue to be screened. The ultrasound system’s size and ease of use helps with these difficult cases just by the way it’s built. It’s very easy to get into difficult spots and the transducers are superb.”

**Anthony Lupetin, MD**

### Exams

Real-time ultrasound evaluation of the right upper quadrant with color Doppler imaging to assess vascular flow and elastography.

### Findings

**Pancreas:** Unremarkable with the tail partially obscured by overlying bowel gas

**Liver:** Homogeneous and normal in morphology

**Gallbladder:** Distended without stones or sludge, wall thickness is within normal limits, and there is no pericholecystic fluid; the common duct is within normal limits, measuring 5 mm

**Right kidney:** Limited images of the right kidney demonstrate no hydronephrosis

**Spleen:** Measures 11.5 cm

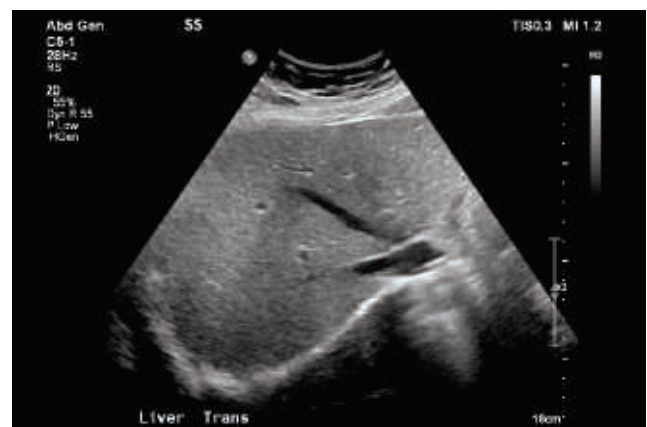**Ascites:** There is no apparent free fluid

### Elastography

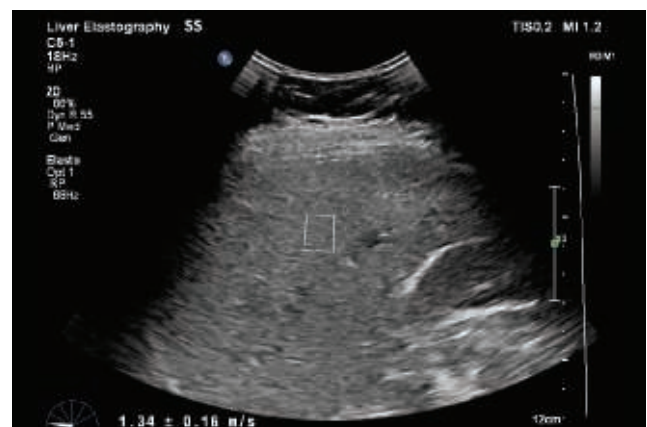Shear wave velocity measures 1.1 m/sec (mean value of 10 measurements).

### Impression

Metavir score F0. No evidence of acute disease.



Liver parenchyma with C5-1 PureWave transducer



Liver stiffness measurement with ElastPQ

## Case 3

# Coma with hepatitis B without mention of hepatic coma

Liver imaging was performed with the high-frequency C9-2 transducer to provide excellent penetration and superb detail resolution, and to allow for color Doppler vessel assessment without compromise during this bedside exam. Liver stiffness was evaluated with the ElastPQ mode on the C5-1 PureWave transducer.

“This patient obviously couldn’t come to the radiology department, and so this was a bedside study, which is easy with the Philips system. With the history of hep B, we scanned to see if the liver disease is progressing to cirrhosis. You can do portable bedside elastography in place of CT and MR.”

**Anthony Lupetin, MD**

### Exams

Grayscale sonography with elastography.

### Findings

**Liver:** Homogeneous without discrete lesion

**Biliary tree:** No intra- or extra-hepatic biliary dilatation; CBD measures 3 mm

**Gallbladder:** Well distended without stones or pericholecystic abnormality

**Pancreas:** Unremarkable with the tail partially obscured by overlying bowel gas

**Spleen:** Measures 8.2 cm

### Elastography

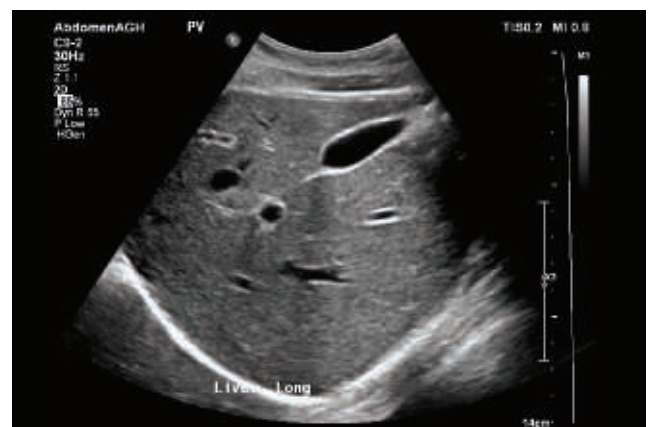Shear wave velocity measures 1.24 m/sec (mean value of 10 measurements).

### Impression

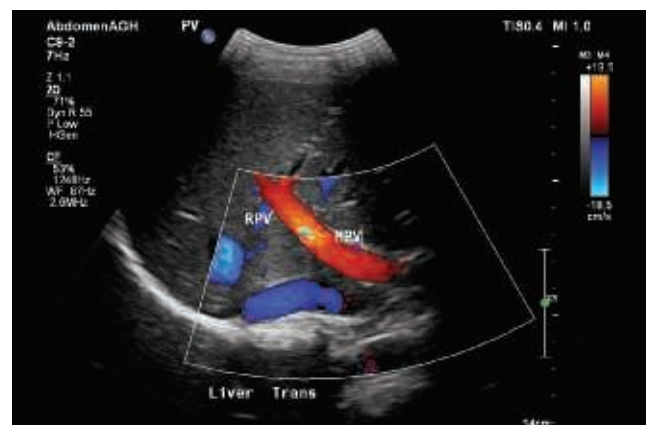Unremarkable abdominal ultrasound. Elastography correlates to Metavir score of F0/F1, normal to mild.

“In some situations you can rule out liver problems with elastography and in other situations you can see something additional, even in the technically difficult patients.”

**Anthony Lupetin, MD**



Liver parenchyma with C9-2 PureWave transducer



Portal vein assessment during bedside exam with C9-2

## Case 4

# Past exposure to CT radiation, scoliotic patient with abnormal liver function enzymes

This case was extremely challenging due to patient's body habitus. The patient presented with severe scoliosis, which means the abdominal organs were slightly shifted and obscured by bowel gas. The PureWave C5-1 transducer was used during this evaluation.

“The patient was showing abnormal liver function enzymes. We wanted to confirm or rule out cirrhosis without exposing the patient to additional ionizing radiation, if possible. We were able to confirm cirrhosis using ultrasound and elastography.”

**Anthony Lupetin, MD**

### Exams

Grayscale sonography with elastography.

### Findings

**Liver:** Coarsened hepatic echotexture is suggestive of cirrhosis but there is no focal hepatic mass

**Gallbladder:** The gallbladder is normal in caliber but contains shadowing stones, and no wall thickening or pericholecystic fluid is identified; sonographic Murphy's sign is negative

**Biliary:** The common duct is normal in caliber, measuring 0.2 cm; there is no intrahepatic biliary ductal dilatation

**Pancreas:** The pancreas is obscured by overlying bowel gas

**Spleen:** The spleen is normal in size (10.7 cm) and homogeneous in echotexture

**Other:** There is trace perihepatic ascites

### Elastography

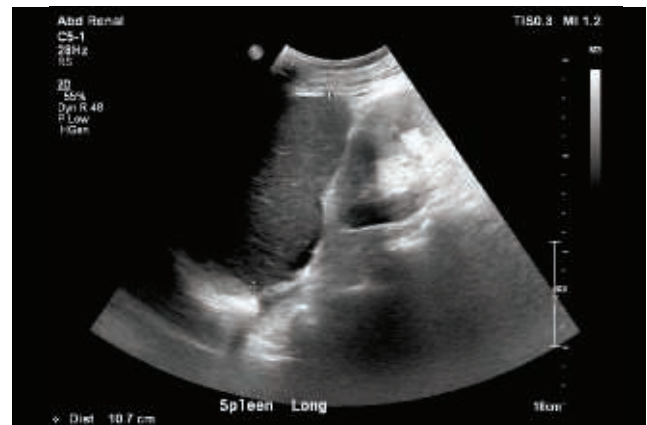Shear wave velocity measures 1.9 m/sec (mean value of 10 measurements).

### Impression

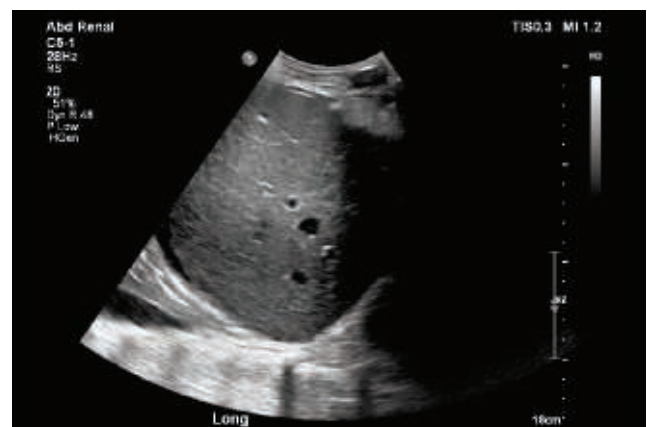Average stiffness of 1.9 consistent with moderate fibrosis. Cirrhotic appearance of the liver without evidence of hypertension. Cholelithiasis. Trace perihepatic ascites.

“We're becoming very sophisticated about liver disease.”

**Anthony Lupetin, MD**



Spleen



Trace of perihepatic ascites



### **Allegheny General Hospital**

Allegheny General Hospital is home to the largest American Society for Radiation Oncology (ASTRO)/American College of Radiology (ACR)-accredited program in the country, and the first and only one in Pittsburgh. Its adult transplant program is among the top 25 in the United States.

The hospital has been recognized by *U.S. News and World Report* as one of the country's best hospitals. Truven Health Analytics (formerly Thomson Reuters Healthcare business) identified the hospital as one of the country's "100 Top Hospitals" and recently named its network of hospitals one of the best healthcare systems in the nation.

“Alone, the imaging modalities CT, MR, and ultrasound can provide a clue that there’s liver disease, but they don’t really tell you how advanced it is.”

**Anthony Lupetin, MD**

