



PHILIPS

IntelliSpace Portal

Neurology

Advanced imaging in ischemic stroke

Ischemic stroke remains a global burden, with almost seven million new cases diagnosed every year¹. Restoring blood flow to salvageable tissue and improving functional outcome remain key challenges in the disease management.

IntelliSpace Portal offers an extensive portfolio of advanced computed tomography (CT) and magnetic resonance imaging (MRI) postprocessing applications, providing valuable information to assist physicians in the visualization and analysis of brain and lumen imaging in ischemic stroke.

Ischemic stroke, a leading cause of adult disability

With more than 25 million survivors, stroke remains a global burden and the third most common cause of disabilities worldwide¹. When reduced blood supply to an area of the brain is suspected, time is critical in order to maximize the potential benefit of endovascular therapy such as intra-arterial thrombolysis or mechanical thrombectomy.

Brain imaging is essential in the management of acute stroke². While a non-contrast CT scan is promptly obtained to rule out brain hemorrhage, CT or MRI angiography are often performed during initial imaging assessment to avoid treatment delay, particularly for patients eligible to receive IV tPA within 3 to 4.5 hours of ischemic stroke symptom onset.

Furthermore, obtaining CT perfusion, diffusion weighted MRI or MRI perfusion is recommended to aid select patients for mechanical thrombectomy within 6 to 24 hours of last known normal^{2,3}.

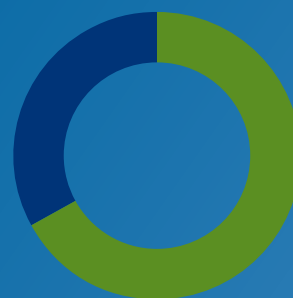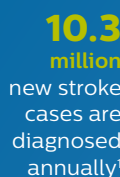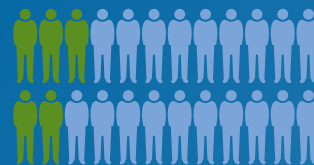IntelliSpace Portal provides valuable information that may support physicians in their assessment

Restoring blood flow to salvageable tissue is one of the key challenges of ischemic stroke management. By providing qualitative and quantitative assessment of brain images combined with analysis and quantification of vascular occlusions, advanced visualization helps physicians assess brain tissue affected by ischemic stroke and determine the access route for recanalization.


IntelliSpace Portal offers an extensive portfolio of advanced CT and MRI post-processing applications, providing valuable information to assist physicians in the visualization and analysis of perfusion and diffusion brain images, as well as the advanced assessment and quantification of vascular lesions from CT and MRI angiography scans.



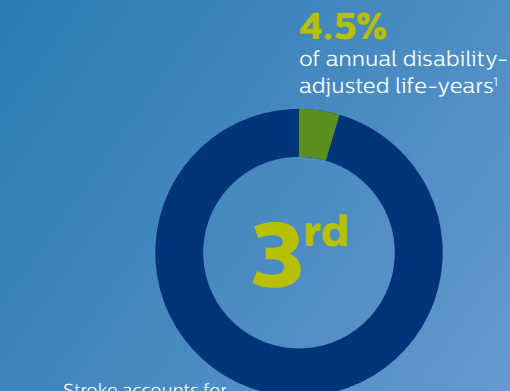
stroke survivors worldwide¹



of all stroke cases are ischemic strokes¹



11.8% of the total burden of disease



CT plays a crucial role in the evaluation of acute stroke

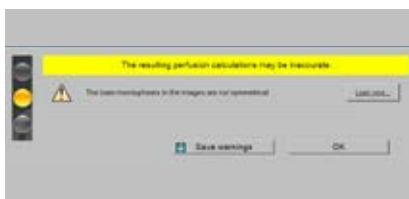
NCCT, CTA and CT perfusion provide valuable clinical information which may help physicians reach informed decisions. Particularly, CT perfusion generates qualitative and quantitative data about changes in image intensity over time, therefore supporting the physician in visualizing the perfusion in brain tissue affected by ischemic stroke. Areas of reduced perfusion, as observed in acute cerebral infarcts, appear as areas of lower signal intensity for both cerebral blood flow and cerebral blood volume, and higher signal intensity for time to peak and mean transition time⁴.

CT Brain Perfusion advanced imaging functionalities

Traffic lights

The quality indicator points at possible acquisition faults that may affect the results.

Highlight: Supports most perfusion scans including jog mode and thin-slice data, and can handle data from multiple vendors.*



Traffic light quality indicator

3D Motion correction

In addition to automated motion correction, the application features a 3D Motion Correction option performing 3D registration and anatomical alignment to address patient movement.

Highlight: Includes removal of selected time points.

Perfusion and summary maps

The application offers quantitative perfusion and summary maps⁵ which may help physicians in determining areas of reduced cerebral blood flow compared to the contralateral hemisphere.

Highlight: The results can be made automatically available on PACS for convenient reviewing.

Time-invariant CT angiography

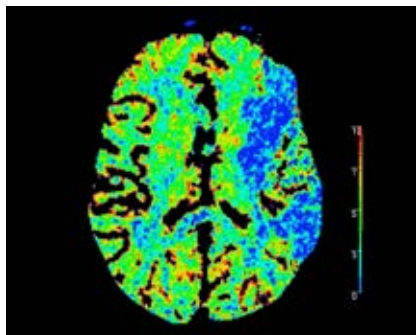
The time-invariant-CT angiography (TI-CTA) preprocessing option is used to reconstruct TI-CTA series from the CT perfusion data.

Highlight: TI-CTA series provide information about arterial, venous and collateral systems⁶.

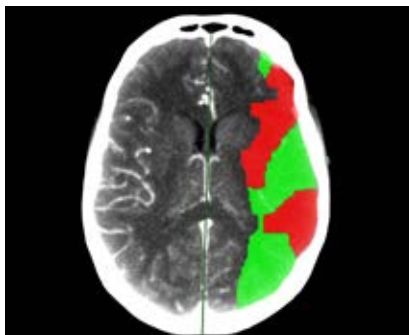
Permeability map

For studies of sufficient scan duration, permeability analysis can be used as an assessment of the contrast agent permeation of the blood-brain barrier.

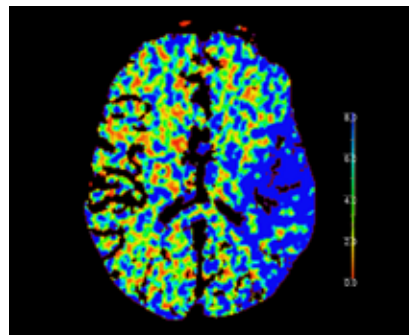
Highlight: Recommended scan duration for calculating permeability results is 210 seconds.



CBV perfusion map



Summary map



Permeability map

* Please contact your local Philips representative for details on multivendor coverage

MRI can provide valuable information for the assessment of ischemic stroke²

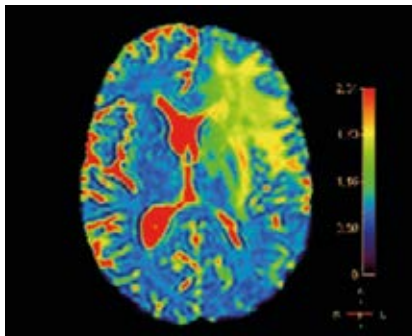
While diffusion weighted imaging was found to be particularly useful for the early evaluation of cerebral ischemia⁷, T2* perfusion MRI is used to help physicians visualize the perfusion in brain tissue affected by ischemic stroke⁸. Furthermore, perfusion-diffusion mismatch was recently shown effective in selecting patients with large anterior circulation vessel occlusion for mechanical thrombectomy^{3,9}. MRI angiography is often performed in the evaluation of stroke sources, aiming to identify the location of large vessel occlusions¹⁰.

Advanced MRI post-processing applications

MR Diffusion

Used to evaluate DWI series and generate parametric maps such as ADC and eADC to help characterize diffusion properties of brain tissue. The advanced diffusion software also offers advanced parametric maps including diffusion kurtosis and IVIM.

Highlight: DWI can be computed at a b-value of choice, from 0 and up to 5,000.

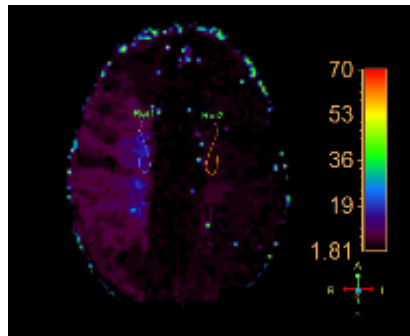


Diffusion map in MR diffusion

MR Neuro perfusion

Designed to analyze dynamic susceptibility contrast variations caused by the passage of a contrast bolus through the vasculature of the brain, assessing brain perfusion.

Highlight: In combination with a diffusion weighted acquisition, the application allows visualization and quantification of diffusion-perfusion mismatch.

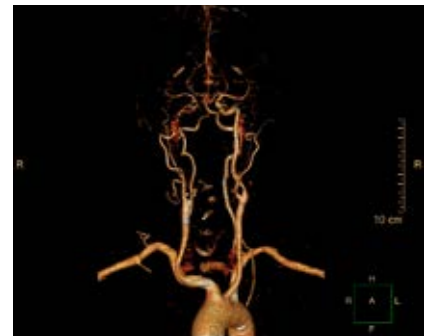

Perfusion map in MR neuro perfusion

MM Advanced vessel analysis

Intended to examine and quantify vascular lesions such as cerebral and carotid stenosis from CTA and MRA scans. The automatic bone removal algorithm provides a clear 3D visualization of the vessels while removing the non-target anatomy.

Highlight: Provides an overall view of the vessels which may assist the physician in determining the access route for recanalization.



Vessels representation in advanced vessel analysis

References

1. Feigin VL et al. Global burden of stroke. *Circulation Research* 2017; 120(3):439-448.
2. Powers WJ et al. Guidelines for the early management of patients with acute ischemic stroke: A guideline for healthcare professionals from the AHA/ ASA. *Stroke* 2018; 49(3):e46-e110.
3. Nogueira RG et al. Thrombectomy 6 to 24 hours after stroke with a mismatch between deficit and infarct. *NEJM* 2018; 378(1):11-21.
4. Heit JJ et al. Perfusion computed tomography for the evaluation of acute ischemic stroke. *Stroke* 2016; 47:1153-1158.
5. Wintermark M et al. Perfusion-CT assessment of infarct core and penumbra: receiver operating characteristic curve analysis in 130 patients suspected of acute hemispheric stroke. *Stroke* 2006; 37(4):979-985.
6. Smit EJ et al. Timing-invariant imaging of collateral vessels in acute ischemic stroke. *Stroke* 2013; 44:2194-2199.
7. Fung SH et al. MR Diffusion imaging in ischemic stroke. *Neuroimag Clin N Am* 2011; 21:345-377.
8. Chavhanet al. Principles, techniques and applications of T2*-based MRI and its special applications. *RSNA* 2009; 29(5):1433-1449.
9. Albers et al. Thrombectomy for stroke at 6 to 16 hours with selection by perfusion imaging. *NEJM* 2018; 378:708-718.
10. Kim BJ et al. Magnetic resonance imaging in acute ischemic stroke treatment. *Journal of Stroke* 2014;16(3):131-145.